

The DEALT* – Method

Special Edition



healing of chronic wounds

on the lower extremity using lipotransfer

(*DEALT = DEbridement with Autologous Lipo-Transfer)

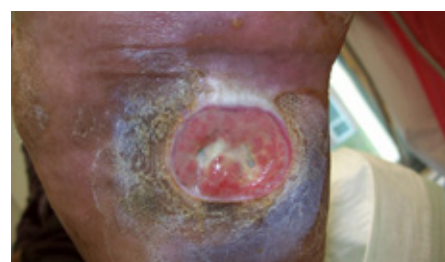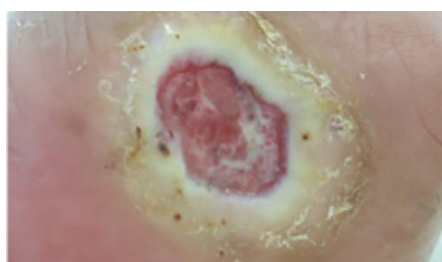
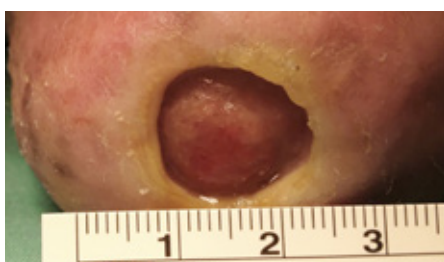
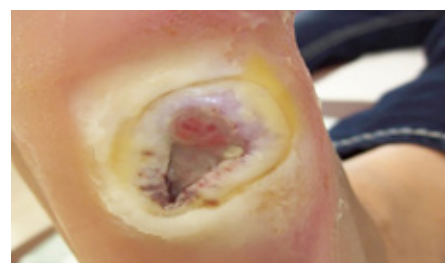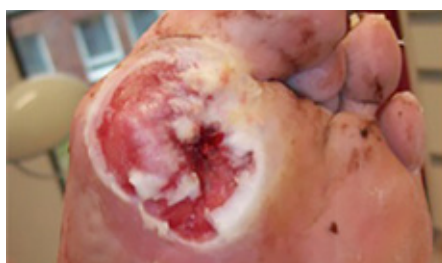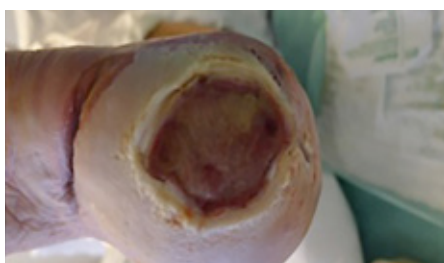The enormous effect of autologous lipotransfer on wound healing – a relatively easy-to-perform, cost-effective, and well tolerated procedure

In a new study published in PRS 2015*, the authors T. Stasch et al. investigated the use of autologous lipotransfer for treatment of chronic diabetic and other foot and lower limb ulcers. "Twenty-six patients with non-healing wounds were treated with surgical débridement and autologous lipotransfer (using the débridement and autologous lipotransfer method). The mean age of the wounds before intervention was 16.7 months. Wound size after débridement averaged 5.1 ± 2.6 cm². On average, 7.1 ± 3.3 cc of lipoaspirate was transferred into the wound area."

Results: "Twenty-two of 25 wounds (88 percent) healed completely within a mean of 68.0 ± 33.0 days. A reduction of wound size by 50 percent was achieved after an average of 4 weeks. In one patient with an ulcer within particularly scarred tissues on the lower limb, a repeated session of lipotransfer led to complete wound healing after another 4 weeks."

Conclusion: "The authors describe a simple and useful technique to improve wound healing in diabetic feet and chronic lower limb ulcers with a background of peripheral vascular disease, where other interventional options to achieve wound healing have failed."

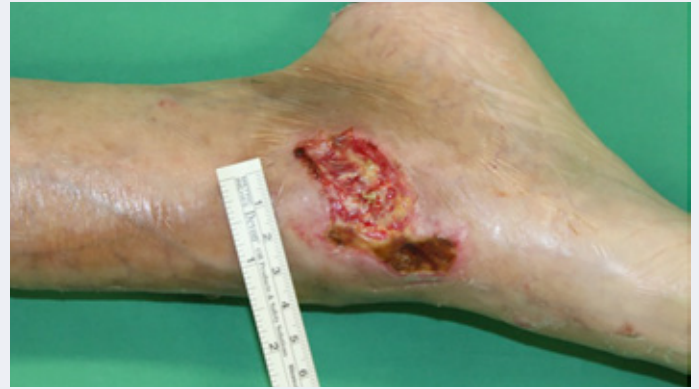(*Stasch T, Hoehne J, Huynh T, De Baerdemaeker R, Grandel S, Herold C. Débridement and Autologous Lipotransfer for Chronic Ulceration of the Diabetic Foot and Lower Limb Improves Wound Healing. *Plast Reconstr Surg.* 2015 Dec;136(6):1357-66)



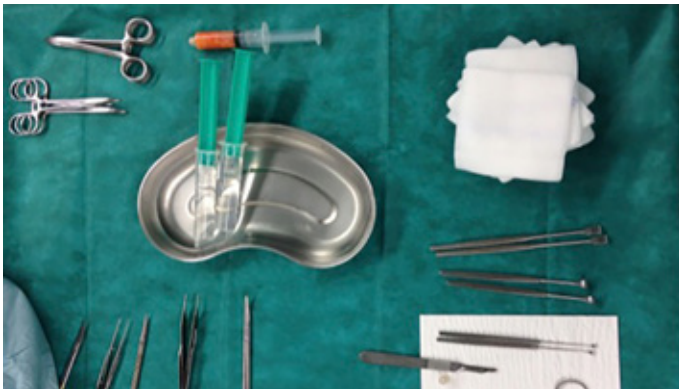Picture 1: Chronic ulcerations on the lower extremity can be very challenging

Problem wounds on the lower extremity responding to lipotransfer

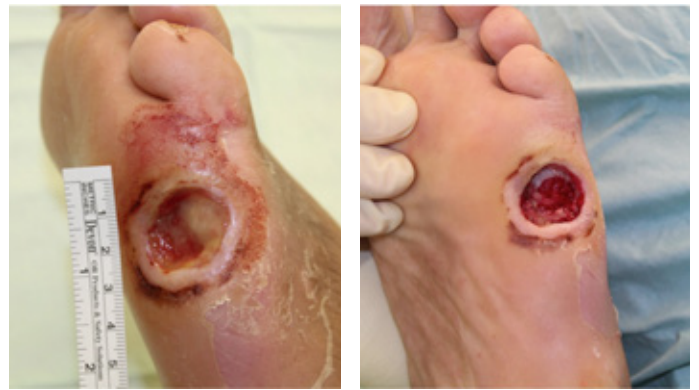- Diabetic feet
- Pressure sores
- Peripheral vascular disease
- Chronic scars
- Post surgical wounds
- Post traumatic wounds



The DEALT procedure



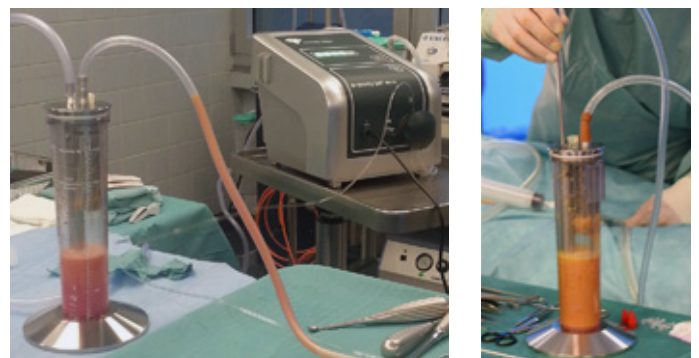
Picture 1: Patient preparation and instruments



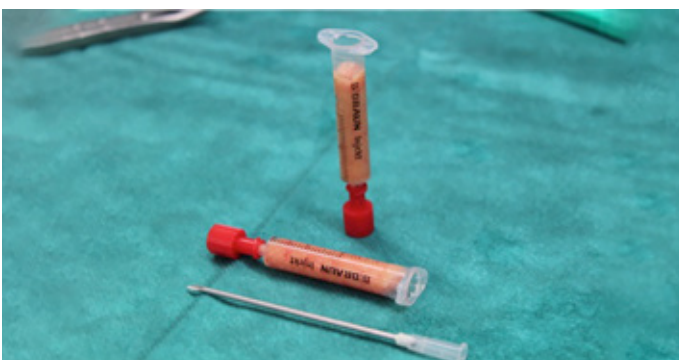Picture 2: Excision of wound margins after sharp debridement of the base of wound



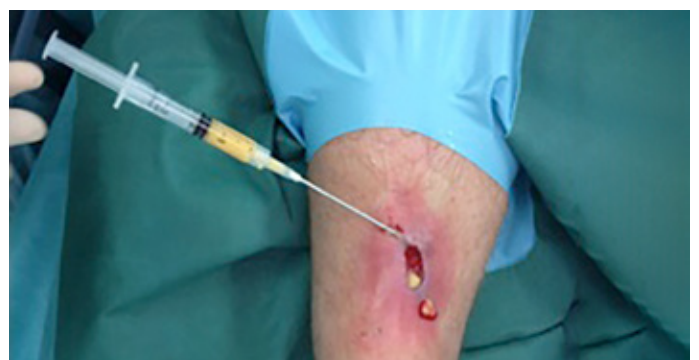Picture 3: Harvesting of fat using body-jet®eco with Fillercollector



Picture 4: Collection of lipoaspirate with Fillercollector

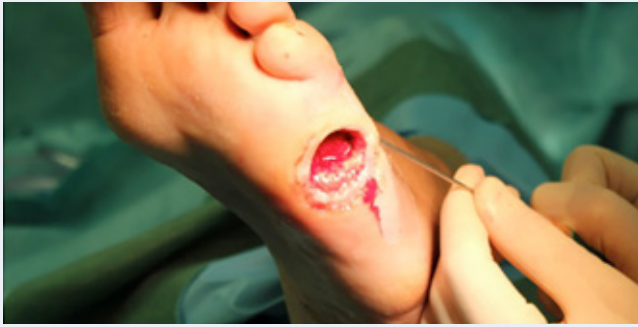

Picture 5: Transfer of fat into 2 ml syringes

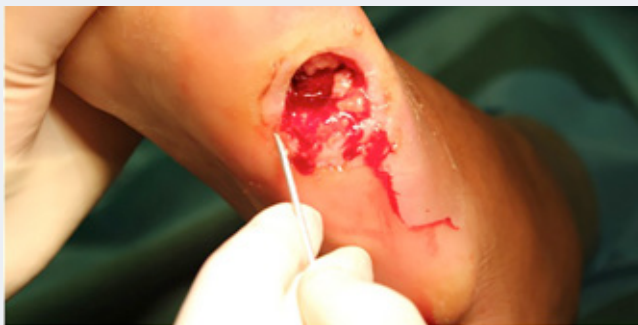

Picture 6: Injection of fat

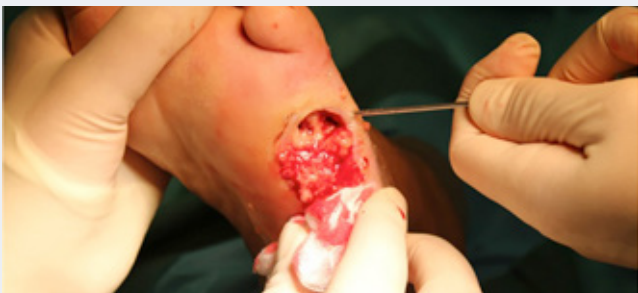Lipotransfer using the DEALT method



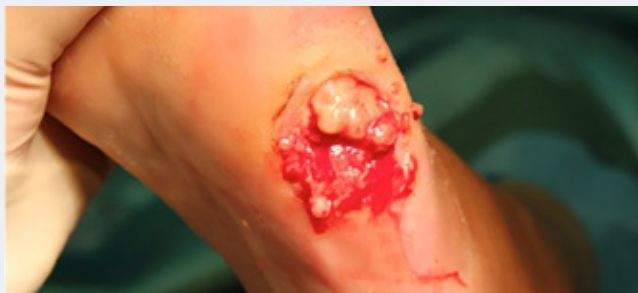Debridement and autologous lipotransfer = DEALT



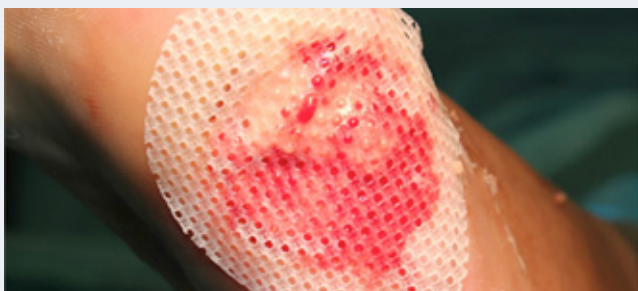Perilesional infiltration from the outside, using a sharp needle



Infiltrating the bottom of wound



Left over fat stays in the wound



Example for dressing: Silicone or petroleum based gauze

Post-op dressing

- Perforated occlusive dressing covered with sterile gauze (e.g. Suprasorb H or OpSite) to absorb wound exudate or
- Intermittent Negative Pressure Wound Therapy



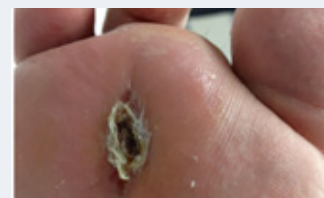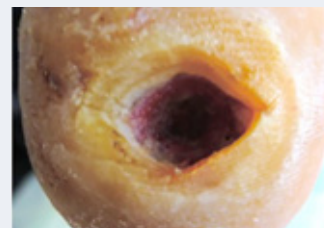
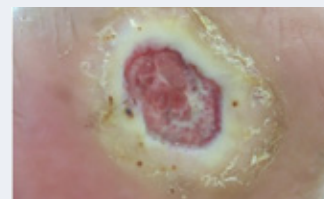
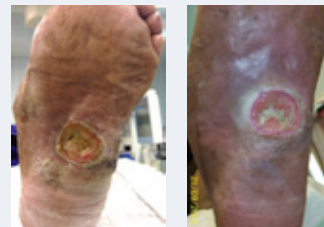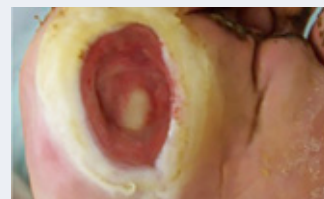Follow-up

- Bed rest for 4-5 days
- Keep wound covered with occlusive dressing for 4-5 days
- Change sterile gauze daily to keep wound surroundings dry
- After 5 days: complete change of dressing
- Limited weight bearing until healing complete
- Orthopaedic shoes (WCS™) prevent recurrence!

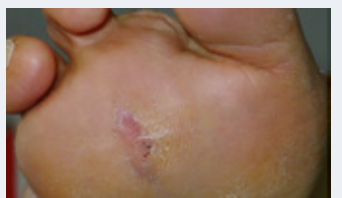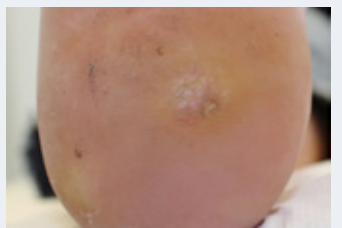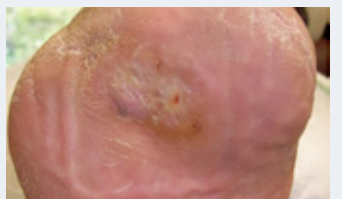
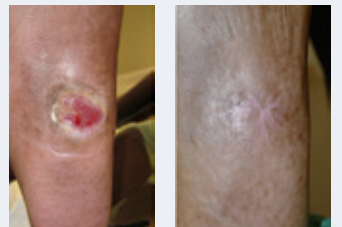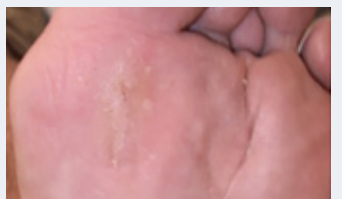Cases of plantar lesions

These recalcitrant wounds had not healed for an average of 16 months. After DEALT complete healing was observed within 2 months.

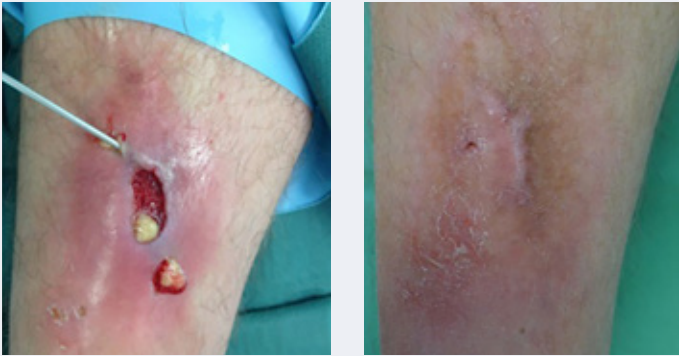
Before Fat Injection



After Fat Injection

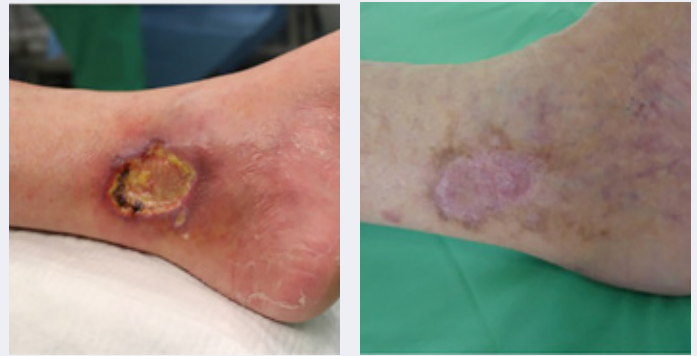

Pretibial lesions

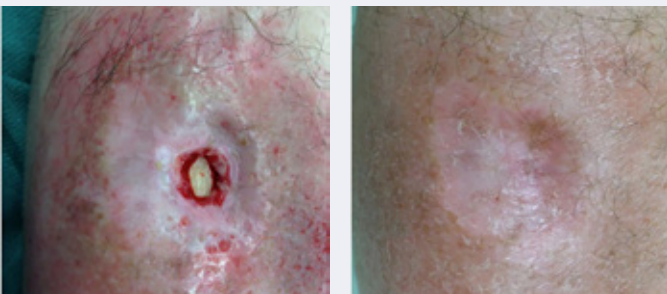


Intra-op fat injection and result after 2 months

Painful leg ulcers



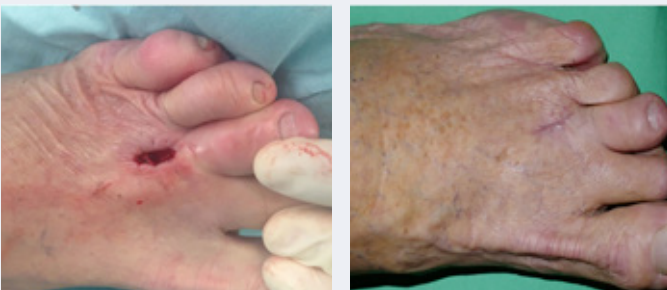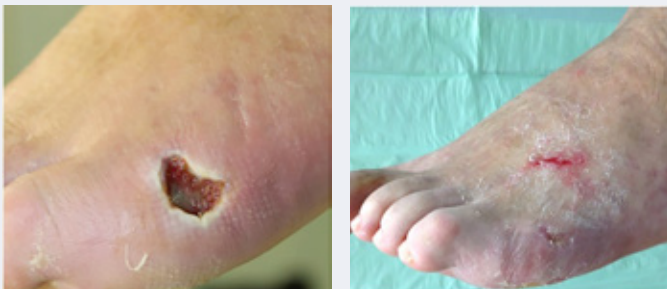
Chronic leg ulcer, very painful – Before and after fat injection and skin graft



Chronic wound with exposed bone before and 3 months after fat injection

Ulcers on the dorsum of the foot

Chronic post-surgical wound healing problems



Chronic wound before and 3 months after fat injection

Why does it work?

Adipose-derived stem cells which are contained within the transplanted fat have been shown to have a positive impact on wound healing, as they not only release growth factors and wound-healing peptides, but also induce new blood vessel formation and fibroblasts, in addition to inhibiting the production of inflammatory cytokines and stimulation of the production of antiinflammatory cytokines.

Summary

- Debridement and Autologous Lipo-Transfer can heal chronic wounds/ulcers very effectively
- Chronic lower limb and foot ulcers can be **DEALT** with to form stable tissue
- Viable fat tissue with high content of adipose stem cells is harvested with body-jet[®]eco and FillerCollector
- Protect granulation tissue (limited weight bearing/use of special orthopedic shoes or inlays)
- Repeat lipofilling when no further progression observed
- Wounds > 10 cm² can be skin grafted when reepithelization takes too long

Author and pictures:

Dr Tilman Stasch
MBCHB, MRCS, MD, F EBOPRAS
Plastic, Reconstructive and Aesthetic Surgeon

human med AG

Wilhelm-Hennemann-Str. 9 • 19061 Schwerin • Germany
Phone: +49 (385) 395700 • Fax: +49 (385) 3957029 • info@humanmed.com
© human med AG 01/2016 • REF 9001031 • Editor: Inge Matthiesen

www.humanmed.com

